

Paging Dr. Google

*A 22 year-old man with
Thrombocytopenia, Anasarca, Fever,
Reticulin Fibrosis, and Organomegaly*

**Jonathan Zipursky MD FRCPC
PGY5 Clinical Pharmacology and Toxicology
University of Toronto**

Disclosures

None

Case

22 year old man

Reason for referral: Ascites, diarrhea, abdominal bloating – progressive x 3 months

Past medical history:

- Asthma

Medications:

- Advair 1 inh BID
- Ventolin prn

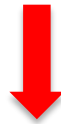NKDA

Social history:

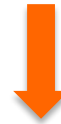- East Asian
- Trade school to become a plumber
- Social alcohol, cigarette, and marijuana use

History of presenting illness (HPI)

- **3 months:** non-bloody diarrhea & 20 lbs of unintentional weight loss



- **3 weeks:** early satiety and “abdominal bloating”



- **1 week:** community hospital just outside the GTA



- **August 2015:** Transferred for a ‘specialist opinion’ and ‘expedited diagnostic work up’

Physical Exam

Vitals: T 38.1 C, HR 138 (regular), BP 123/86, RR 20, 97% RA

Gen: diaphoretic, generally looked unwell

CV/Resp: unremarkable

Abd: massive ascites (bulging flanks, +fluid wave), HSM difficult to appreciate given the degree of ascites

GU: +++scrotal edema

Ext: peripheral edema

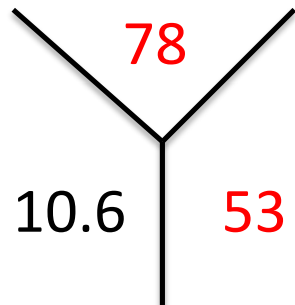
Skin: no rash

MSK: no active joints

Heme: no axillary, inguinal or H&N lymphadenopathy

Investigations

Hematology



Retic: 2

MCV: 79.8

INR: 1.27

PTT: 33.9 sec

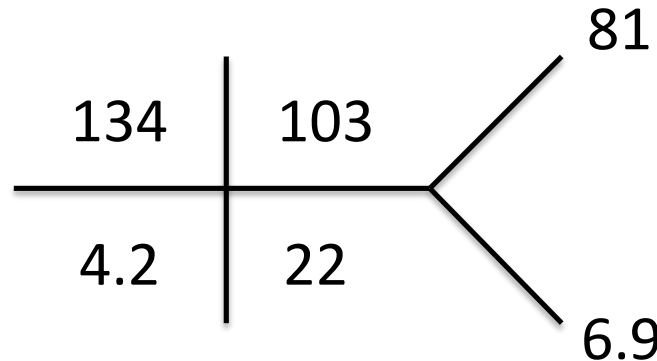
Fibrinogen 3.5

Ferritin: 1310

B12: 241

Normal Igs

Biochemistry



AST 23 T bili 13

ALT 20

ALP 217

GGT 205

LDH 137

Albumin 27

ESR 30 (nl < 20)

CRP 13 (nl < 5)

Remainder of
inflammatory markers
were negative

Paracentesis

- SAAG = 8
- Cytology negative
- C&S/gram stain negative

Lymphoma
HLH
Lymphoprolif

Connective
Tissue
Disease

Infection:

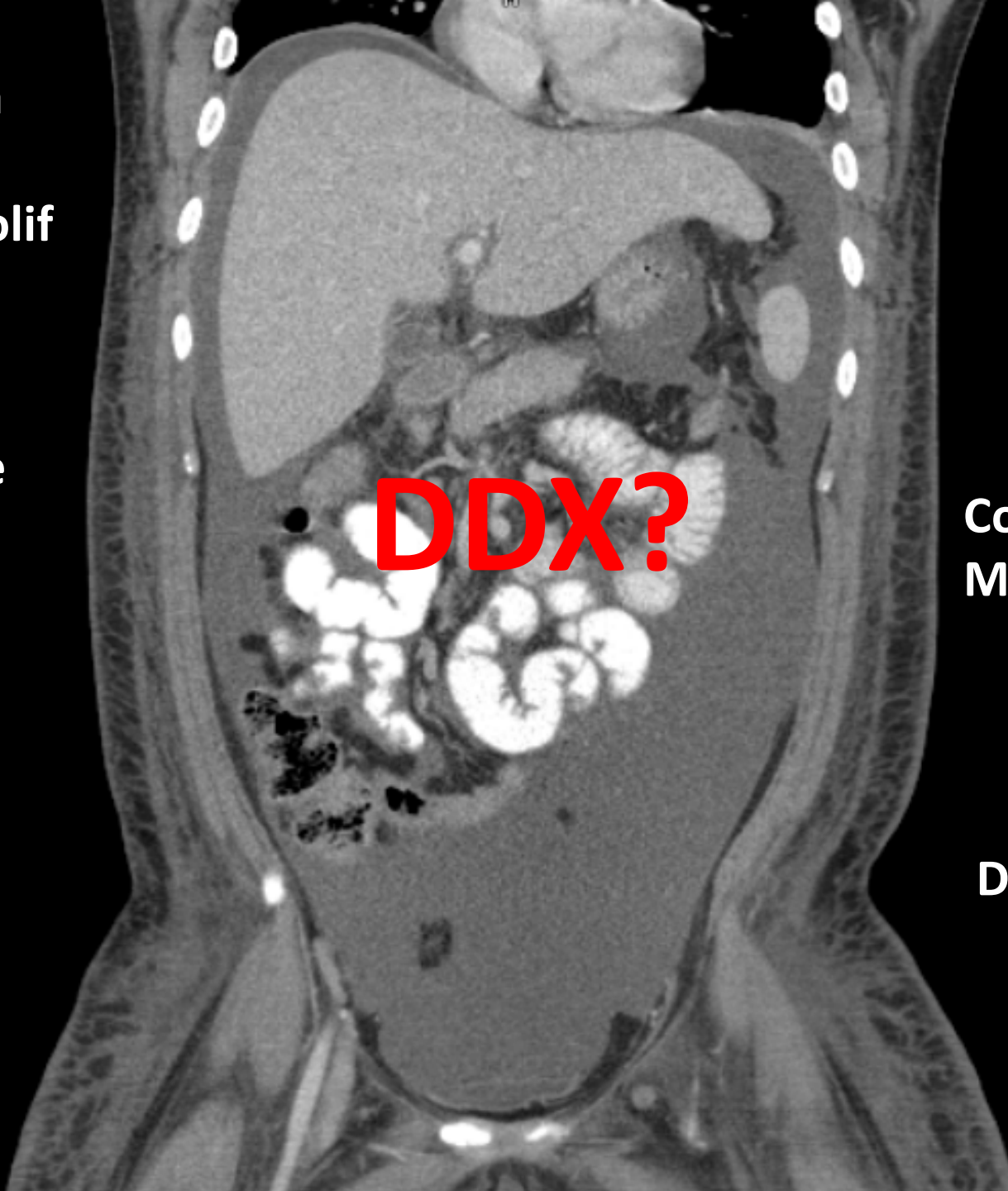
- EBV
- CMV
- TB
- HIV

PLE

**Congenital/
Metabolic**

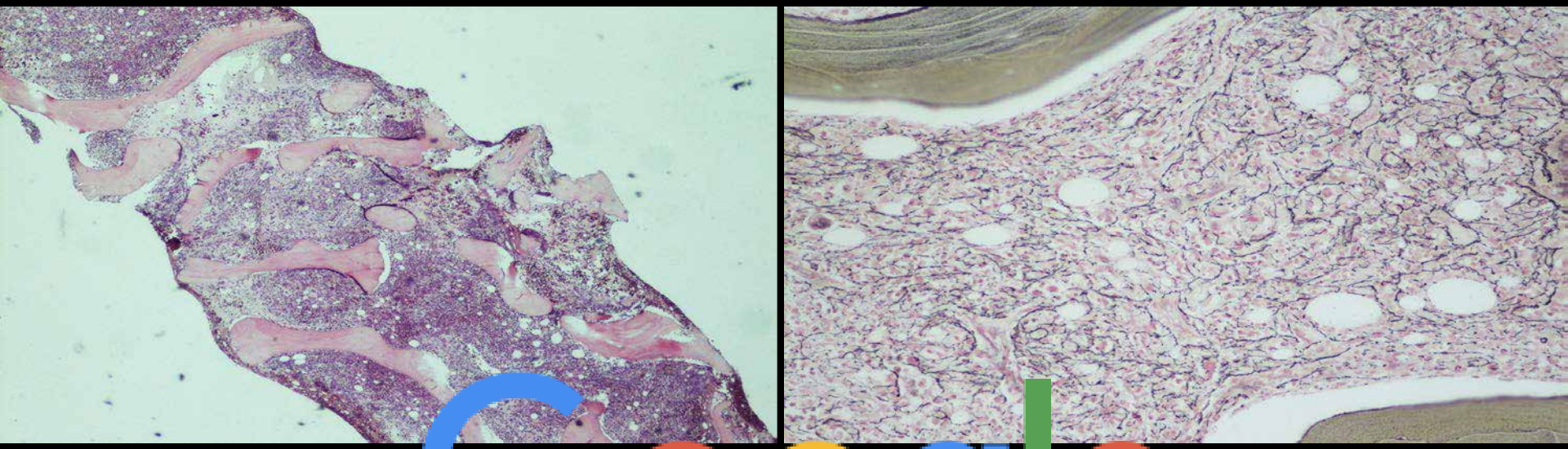
Drug RXN

DDX?



Hospital Course (3 months)

- August to Sept 2015 – no diagnosis, +++ biopsies, treated w/ prednisone



Bon marrow / connective tissue

The Google logo is overlaid on the bottom of the image, partially obscuring the text. The logo consists of the word "Google" in its characteristic multi-colored font: blue 'G', red 'o', yellow 'o', blue 'g', green 'l', and red 'e'.

TAFRO – *Castleman-Kojima disease*

Variant of idiopathic multicentric castleman's disease (iMCD)

Thrombocytopenia

Persistent and noted on admission August 22

Ansarca

Persistent and noted on admission August 22

Fibrosis of bone marrow

Noted on August 27 BMBx

Renal failure

Presented to hospital Sept 26 (Admit #2) with AKI, Creat 147

Organomegaly

Hepatosplenomegaly noted on all imaging studies

American Journal of Hematology 2016

TABLE III. Proposed Diagnostic Criteria for TAFRO-iMCD

1. Histopathological Criteria;
 - Compatible with pathological findings of lymph nodes as TAFRO-iMCD^a
 - Negative LANA-1 for HHV-8 ✓
2. Major criteria;
 - Presents 3 of 5 TAFRO symptoms
 - ✓ Thrombocytopenia ✓
 - ✓ Anasarca ✓
 - ✓ Fever ✓
 - ✓ Reticulin fibrosis ✓
 - ✓ Organomegaly ✓
 - Absence of hypergammaglobulinemia ✓
 - Small volume lymphadenopathy ✓
3. Minor criteria need 1 or more;
 - Hyper/normoplasia of megakaryocytes in bone marrow ✓
 - High levels of serum ALP without markedly elevated serum transaminase ✓

Follow up

- Treated with steroids and Rituxamab
- Jan 2016 – ‘back to normal’
- October 2016 – back to work, off all treatment
- ? long term follow-up and natural history of disease

Paging Dr. Google

A 22 year-old man with Thrombocytopenia, Anasarca, Fever, Reticulin Fibrosis, and Organomegaly

Objectives:

1. Describe a novel case of **TAFRO syndrome**:
Thrombocytopenia, Anasarca, Fever, Reticulin Fibrosis, and Organomegaly
2. Highlight the importance of a multi-faceted interdisciplinary approach to complex medical cases in the 21st century

Thanks to everyone involved in the case!

Sunnybrook Health Sciences Centre

- Dr. Steve Shumak
- Dr. Rena Buckstein
- Dr. Kaveh Shojania
- Dr. Lynfa Stroud
- Dr. Ed Etchells
- Dr. Rajin Mehta
- Dr. Graham Slaughter
- Dr. Michelle Hladanewich
- Dr. Travis Carpenter
- Dr. Zac Feilchenfeld
- Dr. Mina Jamali
- Dr. Marciano Reis
- Dr. Alden Chesney
- Dr. Lisa Chodirker
- Dr. Janey Hsiao
- Dr. Piero Tartaro
- Dr. Michael Bernstein
- Dr. Shady Ashamalla
- Dr. Paul Karanicolas
- Dr. Khalil Sivjee
- Dr. Nick Daneman
- Dr. Shirley Chow
- Dr. Emily Mckeown
- Dr. Zeina Ghorab
- Dr. Maria Jogova
- Dr. Maria Jiang
- Dr. Carolyn Maskens
- Dr. Dasha Yermak
- Dr. Shaun Mehta
- Dr. Stephanie Yang
- Dr. Vlad Dragan
- Dr. Michael Scott
- Dr. David He
- Dr. Daniel Ozier
- Dr. Inna Genkin
- Dr. Robyn Sharma
- Dr. Susan Tran
- Dr. Claudia Posso De Los Rios
- Dr. Allison Pang
- Dr. Bassaam Salim
- Dr. Rachelle Krause
- Dr. Rebecca Titman
- Sabah Khan (CC3)
- Gurtej Sandhu (CC3)
- Dena Sommer (CC3)
- Graeme Hoit (CC3)

The Hospital for Sick Children

- Dr. Carolyn Freedman
- Dr. Joey Latino
- Dr. Mira Leibman

University of Washington-Seattle

- Dr. Corey Casper



Questions?



Toronto Harbour June 2015